Br Ir Orthopt J 2013; **10:** 23–27

Surgical correction of superior oblique palsy: a case series and guideline for surgical choice

GILLIAN COYLE DBO AND CAROLINE J. MACEWEN MD FRCOphth

Orthoptic and Ophthalmology Department, Ninewells Hospital and Medical School, Dundee

Abstract

***Aim*: This paper presents a series of surgical procedures to correct symptomatic superior oblique (SO) palsy. We provide a breakdown of the surgical procedures carried out and provide a simple guideline to aid surgical choice for individual patients.**
***Methods*: This is a retrospective study. Patients who had corrective surgery for SO palsy over the past five years were identified from our surgical database. Hospital and orthoptic notes were used to obtain clinical information. 44 patients were included with a total of 50 operations performed.**
***Results*: Of the 44 patients, 38 (86.4%) required only one procedure to obtain satisfactory improvement of symptoms. In 6 (13.6%) patients a second surgery was necessary to achieve binocular comfort. The amount of deviation corrected in the primary position from each type of operation was: IO disinsertion: 4^{Δ}–20^{Δ} (range), median 11^{Δ}, SO tuck: 10^{Δ}–19^{Δ} (range), median 12^{Δ}, inverse Knapp: 7^{Δ}–28^{Δ} (range), median 16^{Δ}, contralateral inferior rectus recession: 10^{Δ} (only one patient), Harado-Ito: 4–15° of excyclotorsion (range), median 8.5°.**
***Conclusions*: Careful pre-operative assessment is essential to recognise which position(s) of gaze has the greatest ocular misalignment or if torsional diplopia is the main barrier to comfortable BSV. A simple grid chart can then be applied to identify suggested surgery to choose. Full prismatic correction of the vertical deviation in the primary position to within normal vertical fusion range of 5^{Δ} is not necessary to obtain a satisfactory outcome.**

Key words: Preoperative assessment, Superior oblique palsy, Surgical grid

Introduction

Superior oblique palsy (SOP) is a relatively frequent ocular motility defect that presents to the orthoptist and ophthalmologist. A recent study of patients presenting with acute onset diplopia found 53.7% with isolated III, IV or VI cranial nerve palsy, of which IV nerve palsy accounted for 16.1% of the overall cases.[1] SOP can be congenital or acquired, unilateral or bilateral. Clinical features typically include any combination of primary underaction of depression in adduction of the affected eye(s), overaction of the ipsilateral inferior oblique, overaction of the contralateral inferior rectus and underaction of the contralateral superior rectus when full muscle sequelae have developed. Diplopia as a result of SOP may be vertical, torsional (especially in bilateral palsies) and may have a horizontal component which is frequently uncrossed diplopia associated with esotropia.[2] The presentation, pattern of motility dysfunction and aetiology can be varied and atypical.[3]

The aims of this paper are to explore the variation in clinical presentation of SOP in a group of patients presenting to our department, to demonstrate the variation in deviation corrected with surgery, to determine how many surgical procedures were necessary to provide symptomatic relief for patients and to introduce a simple method to aid surgical choice for individual cases.

Methods

Patients were identified from the surgery database of one of the authors (CJM) between January 1995 and March 2012. All surgery was performed or supervised by CJM. Clinical data were obtained retrospectively from orthoptic and hospital case notes. Forty-four patients (31 male, 13 female) were included. Age range at presentation was 12–69 years, mean 40.9 years. The pattern of ocular motility misalignment was used to determine the choice of surgery irrespective of the size of vertical deviation in the primary position. The position of gaze where the vertical deviation was greatest was determined through ocular motility examination, Hess chart and measurement of deviation in nine positions of gaze. Choice of extraocular muscle surgery was then dictated by the greatest position of misalignment. Ipsilateral inferior oblique disinsertion was performed for the greatest misalignment in contralateral elevation. Ipsilateral superior oblique tuck was performed for the greatest misalignment in contralateral depression where there was less contralateral inferior rectus overaction. Contralateral inferior rectus recession was performed for the greatest misalignment in contralateral depression where the overaction of this muscle exceeded the weakness of the original superior oblique palsy. Ipsilateral inverse Knapp was performed where the greatest misalignment was across all depression positions of gaze. Torsion was measured on Lees screen in all cases using the cyclotiltometer. Where torsion was the greatest component of diplopia, a Harado-Ito was the surgical procedure

Correspondence and offprint requests to: Gillian Coyle, Orthoptic Department, Area 6a, Ninewells Hospital, Dundee, DD1 9SY. e mail: gilliancoyle@nhs.net

Table 1. First and second surgical procedures carried out in 44 patients (total number of surgical procedures = 50)

2nd Sx 1st Sx	IO dis 28	Harado-Ito 9	SO tuck 2	Inv Knapp 5
Harado-Ito		1		
SO tuck	2			1
Inv Knapp	1			
Contr IR rec			1	

of choice. Our method was to carry out one procedure at a time, then re-assess the patient with a view to a second procedure if necessary. A total of 50 surgical procedures were carried out, and 6 patients required a second surgical intervention to achieve a satisfactory outcome. The vertical deviation in primary position was as measured by prism cover test and excyclotorsion in primary position on a Lees screen using the cyclo-tiltometer.[4]

Resulting deviation was measured 2 weeks post-operatively and patients were followed up for a minimum of 6 months. The number of follow-up visits varied according to the needs of the patient.

Results

Of the 44 patients, 38 (86.4%) required only one procedure to obtain satisfactory improvement of symptoms as reported by patients. Of these, 28 (63.6%) patients had IO disinsertion, 9 (20.4%) patients had Harado-Ito procedure, 2 (4.5%) had SO tuck and 5 (11.4%) had inverse Knapp.[5] Six out of 44 (13.6%) patients required a second procedure to obtain reported satisfactory improvement of symptoms. Of these, 2 (33.3%) underwent a SO tuck after IO disinsertion, 1 (16.7%) had inverse Knapp after IO disinsertion, 1 (16.7%) had SO tuck after inverse Knapp, 1 (16.7%) had contralateral IR recession after SO tuck and 1 (16.7%) required a repeat Harado-Ito procedure (Table 1).

The surgical procedures performed corrected a variable amount of vertical deviation in primary position or degrees of excyclotorsion (Table 2). Post-operative reduction of primary position vertical deviation (in prism dioptres) was: for IO disinsertion between 4^{Δ}–20^{Δ} (median 11^{Δ}), for SO tuck from 10^{Δ}–19^{Δ} (median 12^{Δ}), inverse Knapp from 7^{Δ}–28^{Δ} (median 16^{Δ}) (Fig. 1), contralateral IR recession corrected 10^{Δ} (1 patient). Harado-Ito surgery corrected 4–15° (median 8.5°) of excyclotorsion in primary position. All patients reported subjective improvement of symptoms from their first surgery despite residual deviation. Improvement in the deficit of ocular motility was evidenced on Hess chart.

Patients who did not require a second procedure were able to control any remaining vertical deviation. A second procedure was performed for those patients with residual symptomatic diplopia in the primary position or in another problematic position of gaze.

None of our patients who underwent one or two surgeries had post-operative reversal of deviation. Patients who had SO tuck had variable post-operative iatrogenic Brown's syndrome with diplopia on upgaze which had been predicted and accepted pre-operatively.

Table 2. Amount of vertical deviation corrected and remaining post-operatively for each surgical procedure as measured in primary position in prism dioptres or excyclotorsion in degrees

Surgical procedure	Median deviation corrected (IQR)	Median post-operative residual deviation (IQR)
IO dis	11^{Δ} (4^{Δ}–20^{Δ})	6^{Δ} (1^{Δ}–17^{Δ})
SO tuck	12^{Δ} (10^{Δ}–19^{Δ})	2^{Δ} (1^{Δ}–7^{Δ})
Inv Knapp	16^{Δ} (7^{Δ}–28^{Δ})	8^{Δ} (1^{Δ}–20^{Δ})
Contr IR rec	10^{Δ} (1 patient)	
Harado-Ito	8.5° (4–15°)	0.5° (0–11°)

Discussion

Surgical correction of ocular motility dysfunction following SO palsy can be achieved providing patients with symptomatic relief and reported subjective improvement in their functional area of binocular single vision. Clinical presentation of ocular motility is varied which may result in difficulty deciding which surgical procedure is appropriate for individual patients. Previous authors have described surgery to one muscle if primary position deviation is less than 15^{Δ}, or two muscles if primary position deviation exceeds 15^{Δ}.[6–7] Studies have also been published comparing efficacy of surgical procedures on correcting the ocular motility deficit with reference to the variation in angle in the nine positions of gaze.[8–9]

Our case series shows that full correction of the vertical deviation in the primary position to within normal vertical fusion range of 5^{Δ} is not necessary to achieve subjective improvement, indeed in the majority of cases a single procedure was sufficient. Residual vertical deviation despite being significant in some cases (Table 2) was controlled by the patient's extended vertical fusion range. In our view, surgical choice was determined by the pattern of ocular motility irrespective of size of deviation in primary position. Indeed the amount of pre-operative vertical deviation varied considerably for each surgical procedure (Fig. 1). Importantly, for IO disinsertion and SO tuck, there was a wide range of pre-operative PCT measurement in primary position but none of our patients, all of whom had the same surgical procedure, was overcorrected. These results indicate that despite the amount of vertical deviation in the primary position, a single muscle surgical procedure cannot be accurately predicted and may be successful with a variety of angles. Generally we operate on only one muscle at a time to ascertain the effect this will have on the ocular motility pattern and ultimately patient symptoms. Patients were made aware that further surgery may be necessary. Our results show that, in the majority of cases, one surgical procedure was sufficient. This retrospective series supports the consideration of tackling one muscle at a time and allowing the patient time to adapt to the resulting change to ocular motility and to utilise their extended vertical fusion ranges if present. For the Harado-Ito procedure, we found overcorrection to incyclotorsion to be common in the immediate post-operative period. However, this

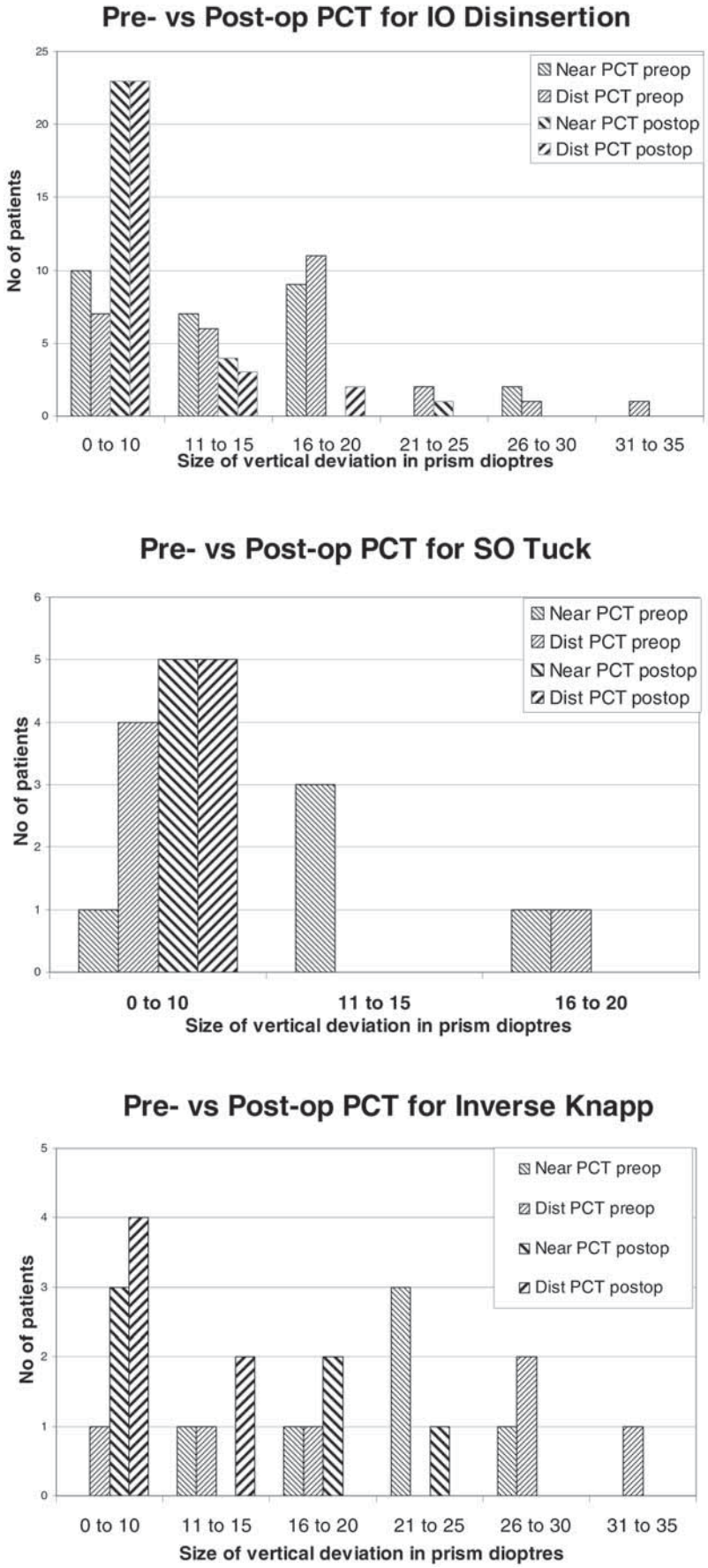

Fig. 1. Graphs for IO disinsertion, SO tuck and inverse Knapp procedures showing the spread of pre- and post-operative size of deviation in primary position as measured in prism dioptres.

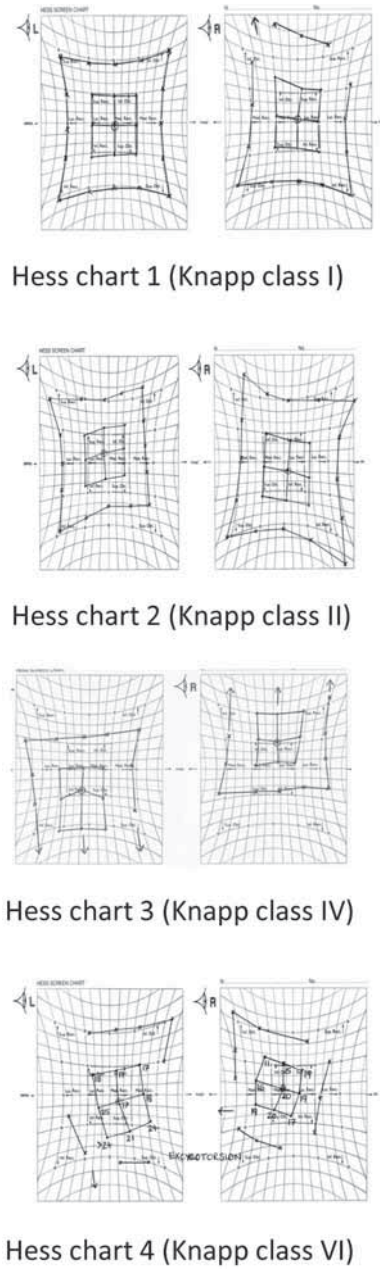

Fig. 2. Examples of Hess charts showing ocular motility misalignment in SOP.

gradually resolved in the first three months to slight excyclotorsion, allowing binocular fusion to occur. Patients should be reassured and prepared for this possibility.[10] The authors recognise that conclusions are based on small numbers of surgical procedures by one surgeon in this series. The retrospective nature and the absence of a control group may also produce some bias.

The variation in clinical ocular motility patterns of SOP are well recognised[11] and are worth revisiting. Fig. 2 shows some of the different common patterns of ocular motility disturbance as illustrated by Hess charts. Hess chart 1 (Knapp class I) shows only a small underaction of the right SO, with the most significant ocular motility deficit being overaction of the ipsilateral IO muscle. Hess chart 2 (Knapp class II) shows moderate/marked underaction of the SO muscle with very little overaction of the ipsilateral IO; there is more overaction of the contralateral inferior rectus muscle. Hess chart 3 (Knapp class IV) shows a moderate/marked underaction of depression in adduction and abduction of the right eye caused by weakness of the SO alone. There is also significant overaction of depression across both adduction and abduction in the contralateral eye. Hess chart 4 (Knapp class VI) shows the significant degree of excyclotorsion caused by a bilateral SO palsy and V pattern esotropia.

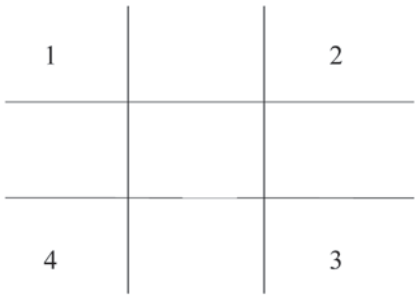

Fig. 3. Surgical planning grid.

Full orthoptic assessment is required pre-operatively to establish the diagnosis and which position(s) of gaze has the greatest ocular misalignment. This was achieved by a combination of some or all of the following:

- ocular movements in free space;
- Hess chart;
- measurement of deviation in nine positions of gaze with loose prisms or synoptophore;
- measurement of torsion with cyclotiltometer adaptation for Lees screen or synoptophore.

Based on our experience, we provide a simple means to assist surgical planning based on the pre-operative pattern of ocular motility. Fig. 3 depicts the familiar nine positions of gaze grid both eyes open with some adaptation. Position 1 is dextroelevation, position 2 is laevoelevation, position 3 is laevodepression and position 4 is dextrodepression. If the deviation is greatest in (as measured using methods previously described):

For (R)SOP:
- position 2 then IO disinsertion is indicated;
- position 3 then SO tuck OR contralateral IR recession is indicated (whichever gives greatest misalignment).

For (L)SOP:
- position 1 then IO disinsertion is indicated;
- position 4 then SO tuck OR contralateral IR recession is indicated (whichever gives greatest misalignment).

For (R) & (L)SOP:
- position 3 *and* 4 then inverse Knapp is indicated.

For unilateral or bilateral SOP:
- excyclotorsion measures greatest then unilateral or bilateral Harado-Ito is indicated.

Once post-operative stability is reached, if further surgery is required then the same chart is used to aid the procedure of choice after full re-assessment.

Table 3. Examples of application of the surgical planning grid

IO Disinsertion	SO tuck	Inverse Knapp	Harado-Ito
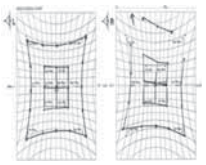	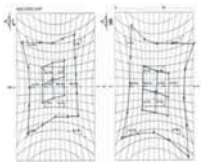	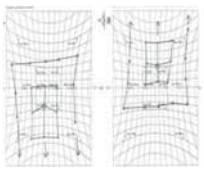	
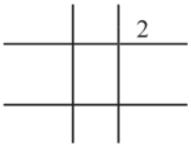	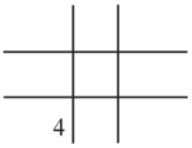	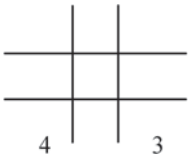	
Pre-op PCT N = 8^{Δ} R/L D = 25^{Δ} R/L Post-op PCT N = 2 R/L D = 3^{Δ} R/L	Pre-op PCT N = 12^{Δ} L/R D = 18^{Δ} L/R Post-op PCT N = 7^{Δ} L/R D = 2^{Δ} L/R	Pre-op PCT N = 25^{Δ} R/L D = 35^{Δ} R/L Post-op PCT N = 10^{Δ} R/L D = 8^{Δ} R/L	Pre-op excyclotorsion = 20 Post-op excyclotorsion = 13

Table 3 provides examples of application of the surgical planning grid.

Full discussion with patients pre-operatively is crucial to explain aims of surgery, expected outcome and that more than one surgical procedure may be necessary to achieve satisfactory symptomatic improvement.

Conclusion

Full pre-operative assessment is required to establish the pattern of ocular misalignment in SOP with particular reference to the variation in angle in the nine positions of gaze. The size of deviation in the primary position need not determine the number of muscles to be operated on and in our experience operating on one muscle at a time is favourable. We provide a surgical planning grid to aid the choice of surgery in individual patients with the aim of re-balancing ocular misalignment exclusive of size of primary position deviation.

The authors declare that they have no competing interests.

References

1. O'Colmain U, Gilmour C, MacEwen CJ. Acute onset diplopia. *Acta Ophthalmol* 2013 (in press).
2. Ansons AM, Davis H. *Diagnosis and Management of Ocular Motility Disorders*, 3rd edition. Oxford: Blackwell Publishing, 2001.
3. Helveston EM, Mora JS, Lipsky SN, *et al*. Surgical treatment of superior oblique palsy. *Trans Am Ophthalmol Soc* 1996; **94:** 315–334.
4. Brown JB. Cyclophoria: a simple measuring device. *Br Orthopt J* 1990; **47:** 70–76.
5. Maurino V, Kwan ASL, Lee JP. Review of the inverse Knapp procedure: indications, effectiveness and results. *Eye* 2001; **15:** 7–11.
6. Prieto-Diaz J, Gamio S, Prieto-Diaz F. Unilateral superior oblique paresis: deviation patterns and surgical indications. *Bin Vis Strabismus Q* 2003; **18:** 201–208.
7. Scott WE, Kraft S. Classification and surgical treatment of superior oblique palsies. I. Unilateral superior oblique palsy. *Trans New Orleans Acad Ophthalmol.* New York: Raven Press, 1986: 15–38.
8. Yanyali A, Elibol O, Talu H, *et al*. A comparative study of the effectiveness of disinsertion and anterior transposition of the inferior oblique in the treatment of unilateral superior oblique palsy. *Strabismus* 2001; **9:** 83–90.
9. Ghazawy S, Reddy AR, Kipioti A, *et al.* Myectomy versus anterior transposition for inferior oblique overaction. *J AAPOS* 2007; **11:** 601–605.
10. Griffiths HJ, Burke JP. Temporary incyclotorsion following surgical correction of bilateral superior oblique palsy. *J AAPOS* 2007; **11:** 65–67.
11. Knapp P. First annual Richard E. Scobee memorial lecture: diagnosis and surgical treatment of hypertropia. *Am Orthopt J* 1971; **21:** 29–37.