

## Diplopia following retinal detachment repair: prisms or surgery long term?

GERALDINE R. MCBRIDE MSc FBDO (LVA Hons) BSc (Hons)

*Department of Orthoptics, Ophthalmology Department, University Hospital Galway, Galway, Ireland*

### Abstract

**Aim:** To discuss the rare complication of diplopia following surgical repair of a primary rhegmatogenous retinal detachment.

**Method:** The case of a 52-year-old woman who underwent cryo-buckle surgery for her retinal detachment repair is described from the perspective of her post-operative orthoptic management.

**Results:** A conservative approach was taken as the patient's diplopia was controlled by the use of prisms.

**Conclusion:** Options to control diplopia include prisms, Botox and strabismus surgery; however, the conservative approach of incorporated prisms to control a small strabismus is generally sufficient.

**Key words:** Cryo-buckle surgery, Diplopia, Primary rhegmatogenous retinal detachment, Prisms, Strabismus surgery

### Introduction

This patient experienced the rare complication of diplopia following surgical repair of a primary rhegmatogenous retinal detachment. Although diplopia following retinal detachment surgery is a known complication, the occurrence at University Hospital Galway (UHG) is very low, with 5 cases presenting to the orthoptic service during a 4-year period (Table 1).

The reported annual incidence of retinal detachment is approximately 10–15 per 100 000.<sup>1</sup> Individuals with myopia, previous cataract surgery, ocular inflammation or ocular trauma are at a higher risk.<sup>1</sup> There are three types of retinal detachments: rhegmatogenous, tractional and exudative. Rhegmatogenous is the most common.<sup>2</sup> The most important risk factor for rhegmatogenous retinal detachment is axial myopia, with higher myopes being at higher risk.<sup>2</sup> In our case rhegmatogenous retinal detachment was probably a result of high myopia. Symptomatic posterior vitreous detachments can result in acute retinal tears and this then frequently leads to a rhegmatogenous retinal detachment.

There are no guidelines from the Royal College of Ophthalmologists or the British and Irish Orthoptic

Society regarding management of diplopia following retinal detachment surgery. Guidelines exist for the management of retinal detachment because it is a potentially sight-threatening condition. The Royal College of Ophthalmologists recommends urgent surgery, i.e. within 24 hours, for patients who present with a retinal detachment where the macula is still on, as this will lead to a better visual outcome.<sup>1</sup>

The surgical correction of retinal detachment includes scleral buckling combined with vitreous cavity gas injection, pars plana vitrectomy or pneumatic retinopexy.<sup>2</sup> Currently a vitrectomy with gas/oil is the procedure of choice in repairing the majority of retinal detachments, but scleral buckling is still chosen in some situations. Scleral buckling involves the use of silicone sponges or bands to indent the sclera over the site of the retinal hole; if the hole is sealed, it will allow the retinal pigment epithelium pump mechanism to remove the sub-retinal fluid.<sup>2</sup> Cryotherapy is used to incite an area of inflammation, which aims to seal the break.<sup>2</sup> Scleral buckling as a procedure for correcting retinal detachment has a high re-attachment rate with good long-term attachment and good visual outcomes.<sup>3</sup> Scleral buckling risks include pain, infection, buckle extrusion and diplopia.<sup>3</sup> The removal of a buckle due to a post-operative complication carries the risk of re-detachment. One study reported that 6 cases (8.3%) re-detached following scleral explant removal, with 5 of those cases re-detaching within 6 months of explant removal, and one 2 years after removal.<sup>4</sup>

### Case report

A 52-year-old non-smoking female patient was transferred from another hospital with a left inferotemporal macula-on retinal detachment. There was a history of asthma, hypothyroidism, and impaired glucose tolerance following gastric bypass surgery. Her medications were Eltroxin 100 µg once daily, Desurin 400 mg once daily, Vitamin B12 injections monthly, and Seretide 250 Evohaler 2 puffs twice daily. The patient's refraction was right  $-2.50/-1.50 \times 180$  and left  $-3.50/-4.00 \times 170$ . The patient's occupation was hospital cook.

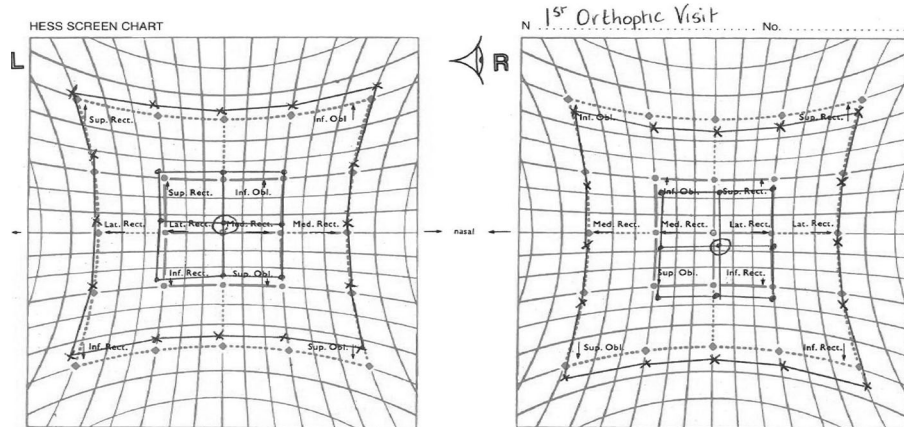
On presentation the patient had a 2-day history of photopsia and a 7-day history of reduced vision in the left eye. The patient had a history of left amblyopia. Visual acuity was right 0.000 and left 0.300 logMAR. The patient was diagnosed with a left shallow inferotemporal retinal detachment with an inferior retinal hole and intraretinal haemorrhages. The patient underwent

*Correspondence and offprint requests to:* Geraldine McBride, Senior Orthoptist, University Hospital Galway, Galway, Ireland. e-mail: geraldine.mcbride@hse.ie

**Table 1.** Description of patients presenting with diplopia following retinal surgery

Patient	Procedure	Manifest deviation near	Manifest deviation distance	Long-term management	Additional notes
1	L cryotherapy + buckle	3 R/L	4 R/L	Incorporated prism	Diplopia after removal of buckle
2	R cryotherapy + vitrectomy	4 R/L	3 R/L	Incorporated prism	Diplopia 3 weeks after surgery
3	L cryotherapy + buckle		4 L/R	Incorporated prism	Diplopia after removal of buckle
4	L cryotherapy + buckle		12 L/R	Incorporated prism	Diplopia 3 days after surgery
5	L vitrectomy + cryotherapy	3 L/R	18 L/R	Occlusion	Diplopia 7 months after surgery

Source: Orthoptic Service University Hospital Galway, 2012–2015.



**Fig. 1.** Hess chart on the first orthoptic visit showing left hyperdeviation in all positions of gaze, but otherwise no restrictions, under-actions or over-actions.

left cryo-buckle drainage surgery under general anaesthetic the following day. Cryopexy was applied, sub-retinal fluid drained externally and a 279 silicone buckle fitted under the lateral and inferior recti. One week later, the patient reported a 4-day history of vertical diplopia at night-time. The patient was seen by the vitreoretinal (VR) surgeon who confirmed diplopia and referred the patient to orthoptics, which she attended the following day.

On her first orthoptic examination visual acuity was right 0.000 and left 0.300, using the logMAR acuity chart. The cover test with glasses for near showed a slight exophoria and slight left hyperphoria with good recovery. In the distance a slight left exotropia with left hypertropia with diplopia was found. The ocular movements were full and convergence was binocular to 6 cm, with either eye diverging at this point. Bagolini glasses for near proved binocular single vision (BSV); however, the left eye superior image was intermittently suppressing. In the distance vertical diplopia was proven. For near the prism fusion range was 40<sup>Δ</sup> base out (BO) – 18<sup>Δ</sup> base in (BI) and stereopsis was 170" of arc using the Frisby stereo-test. The prism cover test for near was 6<sup>Δ</sup> L/R 10<sup>Δ</sup> BI and for distance 12<sup>Δ</sup> L/R 10<sup>Δ</sup> BI. The Hess chart showed left hyperdeviation in all positions of gaze, but otherwise no restrictions, under-actions or over-actions (Fig. 1). The working diagnosis was left hyper-tropia secondary to scleral buckle retinal detachment surgery. However, as there was a history of amblyopia another consideration is that the procedure had decompensated an underlying phoria. A 12<sup>Δ</sup> base down Fresnel

prism was fitted to the distance area of left varifocal lens, and the patient was advised to obtain single-vision glasses for the fitting of prisms. Review was arranged for 2 weeks later.

On her second orthoptic examination the patient reported that the Fresnel prism was helpful for primary gaze but not in other positions of gaze, but this could have been related to the induced peripheral area distortions from the varifocal lens combined with the distortions from the high astigmatic corrections when viewing away from the optical centre. Worth's lights proved BSV was present with the Fresnel prism and the remainder of the orthoptic examination was unchanged from the first visit. A 12<sup>Δ</sup> base down Fresnel prism was fitted to left distance single-vision lens. At this visit the VR surgeon also reviewed the patient; he decided against the removal of the buckle due to the possibility of re-detachment. Referral to a strabismologist for the surgical correction of the diplopia was discussed with the patient, but she declined as she did not wish to undergo further ophthalmic surgery.

Six months after the retinal detachment surgery the patient was reviewed at the orthoptic clinic, where her orthoptic assessment was unchanged and she was happy using incorporated prisms split between the distance vision lenses as dispensed by her optometrist.

**Discussion**

In one study 3.8% of patients who underwent a scleral buckling procedure developed diplopia: in 71% of these

**Table 2.** All retinal surgical procedures carried out by the UHG vitreoretinal (VR) surgeon

Procedure	No. of patients
Vitrectomy ± non-buckle additional procedure	489
Vitrectomy plus buckle insertion	46
Cryotherapy	66
Cryotherapy plus buckle insertion	61
Removal of buckle	13
Total VR procedures	662
No. of procedures requiring buckle insertion	129
% of buckles removed	10.08%
% of diplopia cases per total VR procedures	0.755%

Source: University Hospital Galway Operations Record Book, 2012–2015.

cases it was as a result of mechanical restriction to one of the muscles.<sup>5</sup> The authors reported that there was no association between the position of the buckle and the muscle affected.<sup>5</sup> An earlier study of 68 patients with diplopia following scleral buckling showed that 65% developed a restriction of ocular movements following surgery and that there was a correlation between the number of extraocular muscles the buckle was placed under and the number of positions of gaze likely to be restricted ( $p = 0.032$ ).<sup>6</sup> They concluded that in 87% of patients the diplopia could be related to the position of the scleral buckle and that a second retinal detachment procedure increases the likelihood of diplopia ( $p = 0.0297$ ).<sup>6</sup> A study proposed that when there are no obvious restrictions to eye movements or a reported macular translocation, patients who had weak fusional reserves before the retinal detachment may experience post-operative diplopia because they do not have the capacity to adapt following surgery.<sup>7</sup> From the UHG experience it can be stated that all patients experienced vertical diplopia rather than horizontal diplopia, and this could be linked to smaller vertical fusional reserves. This experience is similar to a study of 821 patients who underwent scleral buckling surgery: post-operatively 12 patients developed diplopia (1.5%), with 10 of these reporting vertical diplopia (83%).<sup>8</sup>

The reported incidence of diplopia following retinal detachment surgery has varied from 1.5% to 25%.<sup>8,9</sup> Evidence of the incidence rate comes only from retrospective case reviews from various hospitals. As case reviews report a variable follow-up time, this might contribute to the variable incidence rate, with some units that specialise in VR surgery and perform significantly more surgeries having a lower rate of complications. At UHG the incidence of diplopia following retinal surgery during a 4-year period (2012–2015) is 1 case per 132 retinal procedures (Table 2).

There is controversy as to whether removal of the buckle should be the first stage in managing a patient with diplopia. In one study, 50% of patients had resolution of the diplopia following buckle removal;<sup>8</sup> however, other studies found no benefit of buckle removal on the motor alignment and resolution of diplopia.<sup>10,11</sup> At UHG there have been 2 cases (40%) of diplopia following buckle removal. In this case the VR surgeon advised against the removal of the buckle due to the high risk of re-detachment.

It has been concluded that prisms are the best management for diplopia following scleral buckling

surgery.<sup>5</sup> In one study where the incidence of diplopia following retinal detachment was 4.8% (15 patients), fusion was restored using prisms in 73% (11 patients), of which 7 patients required long-term incorporation of the prism into their glasses.<sup>12</sup> Of the patients who did not respond to prismatic control, 1 had torsional diplopia and 2 had intermittent suppression.<sup>12</sup> The fourth patient had a large vertical deviation measuring  $14^\Delta$ , but when the scleral buckle was removed the deviation reduced to  $2^\Delta$ , which the patient was able to control.<sup>12</sup> At UHG we have had 1 patient who did not tolerate prisms and opted to use an occlusive contact lens over other management options offered.

Strabismus surgery should be considered when diplopia cannot be controlled with prisms, or as a long-term alternative to prism use. There have been mixed reviews as to its suitability as a method of diplopia correction. In one study strabismus surgery was performed successfully on only 3 patients; the authors then concluded it is an efficient method of eliminating diplopia.<sup>8</sup> In contrast, another study concluded that surgical correction of diplopia was technically difficult to perform and the results were less predictable than other forms of strabismus surgery.<sup>9</sup> A 20-year retrospective review of patients who underwent strabismus surgery following retinal detachment repair identified 25 patients; the average time between the retinal detachment surgery and the onset of diplopia was 4 months (range 0–42 months), and the average time between retinal detachment and strabismus surgery was 52 months (range 3–480 months).<sup>10</sup> All the patients had undergone scleral buckling procedures, and in addition 48% had cryotherapy.<sup>10</sup> A successful outcome from a single strabismus surgery was achieved in 36% of cases, increasing to a 72% success rate after multiple strabismus surgeries. Multiple strabismus surgeries (2–4 procedures) were required in 52% of cases.<sup>10</sup> An adjustable suture surgery was performed in 85% of cases.<sup>10</sup> The authors concluded that smaller horizontal squints had better motor (BSV) outcomes ( $p = 0.005$ ), and those showing less restriction on forced duction testing were significantly associated with better BSV outcomes after one strabismus surgery ( $p = 0.05$ ).<sup>10</sup> No association was reported between motor success and operation on the fellow eye ( $p = 0.1$ ) or scleral buckle removal ( $p = 0.99$ ).<sup>10</sup>

An alternative to strabismus surgery is botulinum toxin. In a 24-year retrospective review, 140 patients received botulinum toxin injections to control their diplopia following retinal detachment surgery.<sup>9</sup> To achieve lasting symptomatic relief 1 injection was sufficient in 23.6% of cases, with 50.5% requiring 2 injections.<sup>9</sup> The authors identified after a multivariate analysis that visual acuity in the originally affected eye was the only factor associated with lack of restoration of fusion.<sup>8</sup> Complications from the injections were seen in only 2.9% of patients.<sup>9</sup>

## Conclusion

The UHG patients were successfully managed using a conservative approach with prisms, with only 1 patient choosing to use an occlusive contact lens in the long

term. Review of the UHG surgical logbooks has allowed us to identify our local incidence rate based on a single VR surgeon, thus allowing us to better inform future patients regarding the likelihood of diplopia occurring following retinal surgery.

The author would like to thank Mr Frank Kinsella, Consultant Ophthalmic Surgeon, University Hospital Galway for his input, support and guidance, and permission to access his surgical logbooks. The author reports no conflicting interests.

## References

1. Turner G. The Royal College of Ophthalmologists Ophthalmic Services Guidelines: Management of acute retinal detachment. 2010. Available at: [https://www.rcophth.ac.uk/wp-content/uploads/2014/12/2010\\_PROF\\_064\\_OSG-Retinal-Detachment-June-2010.pdf](https://www.rcophth.ac.uk/wp-content/uploads/2014/12/2010_PROF_064_OSG-Retinal-Detachment-June-2010.pdf) [accessed 22 May 2016].
2. Borman AD, Poulson A. Retinal detachment: a new perspective. *Optometry Today* 2008; [April]: 30–40.
3. Sodhi A, Leung LS, Do DV, *et al.* Recent trends in the management of rhegmatogenous retinal detachment. *Surv Ophthalmol* 2008; **53**: 50–67.
4. Deokule S, Reginald A, Callear A. Scleral explants removal: the last decade. *Eye* 2003; **17**: 687–700.
5. Goezinne F, Berendschot TT, van Daal EW, *et al.* Diplopia was not predictable and not associated with buckle position after sclera buckling surgery for retinal detachment. *Retina* 2012; **32**: 1514–1524.
6. Spencer AF, Newton C, Vernon SA. Incidence of ocular motility problems following scleral buckling surgery. *Eye* 1993; **7**: 751–756.
7. Kasbekar SA, Wong V, Young J, Stappier T, Durnian JM. Strabismus following retinal detachment repair: a comparison between scleral buckling and vitrectomy procedures. *Eye* 2011; **25**: 1202–1206.
8. Sauer A, Bouyon M, Bourcier T, Speeg-Schatz C. Diplopia complicating scleral buckling surgery for retinal detachment. *J Fr Ophthalmol* 2007; **30**: 785–789.
9. Gardner R, Dawson EL, Adams GG, Lee JP. The use of botulinum toxin to treat strabismus following retinal detachment surgery. *Strabismus* 2013; **21**: 8–12.
10. Rabinowitz R, Velez FG, Pineles SL. Risk factors influencing the outcome of strabismus surgery following retinal detachment surgery with scleral buckle. *J AAPOS* 2013; **17**: 594–597.
11. Wong V, Kasbekar S, Young J, *et al.* The effect of scleral exopiant removal on strabismus following retinal detachment repair. *J AAPOS* 2011; **15**: 321–333.
12. Fison PN, Chignell AH. Diplopia after retinal detachment surgery. *Br J Ophthalmol* 1987; **71**: 521–525.